

3D RECONSTRUCTION of LEFT SCAPULA FRACTURE

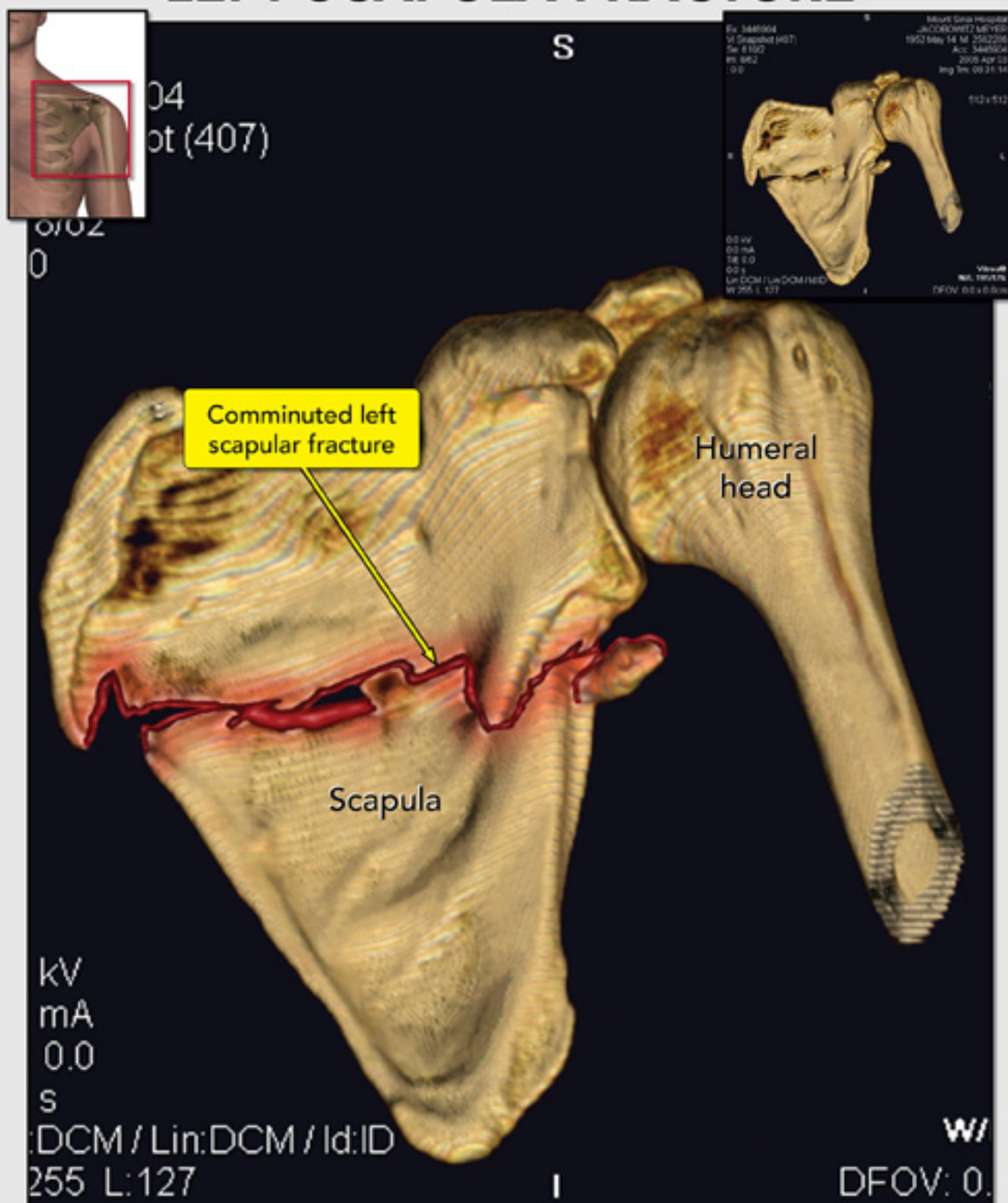


IMAGE: 8/62

ANTERIOR VIEW 04/03/06

Pre-operative CT-3D Reconstruction of a left comminuted scapula fracture