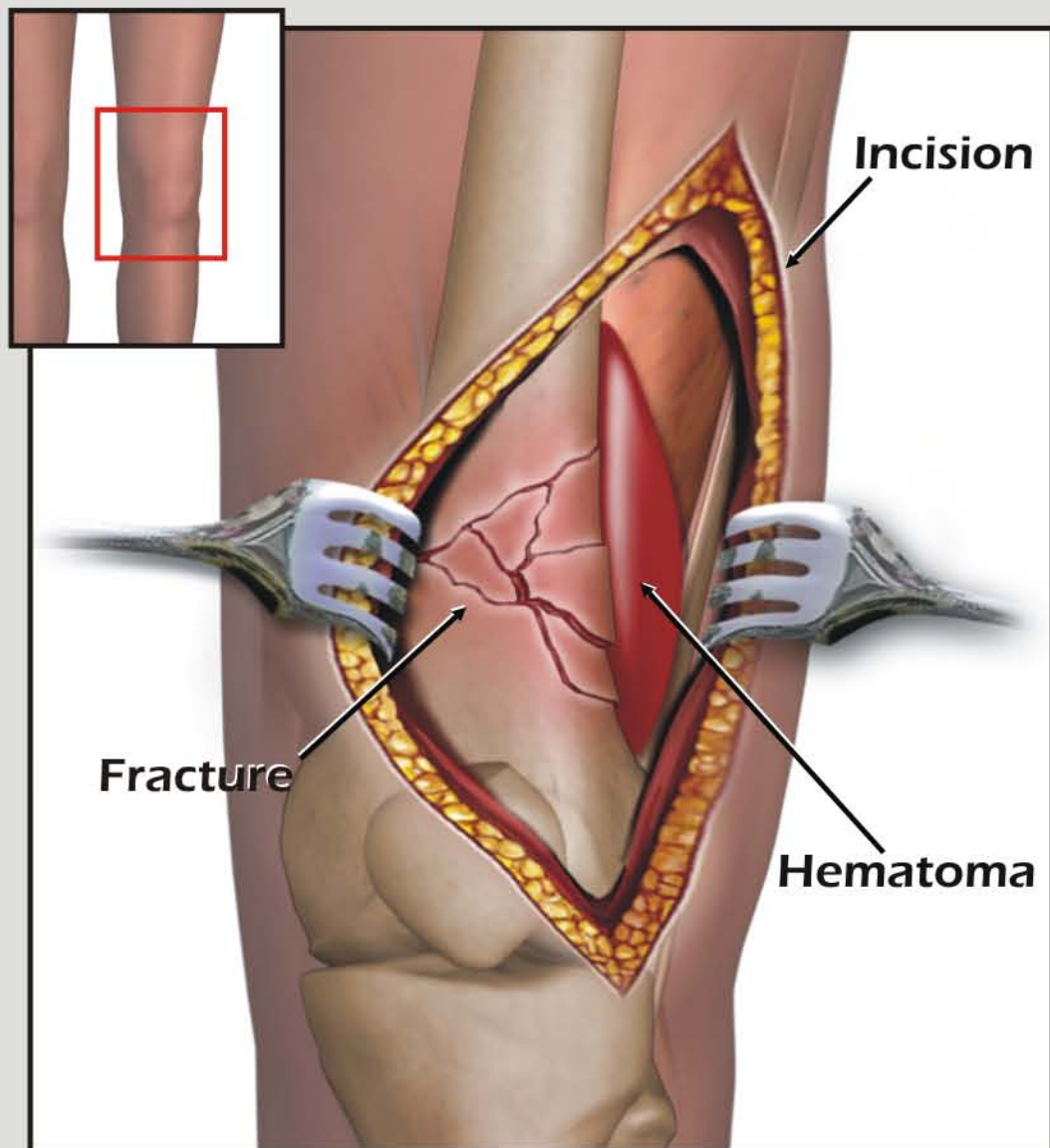
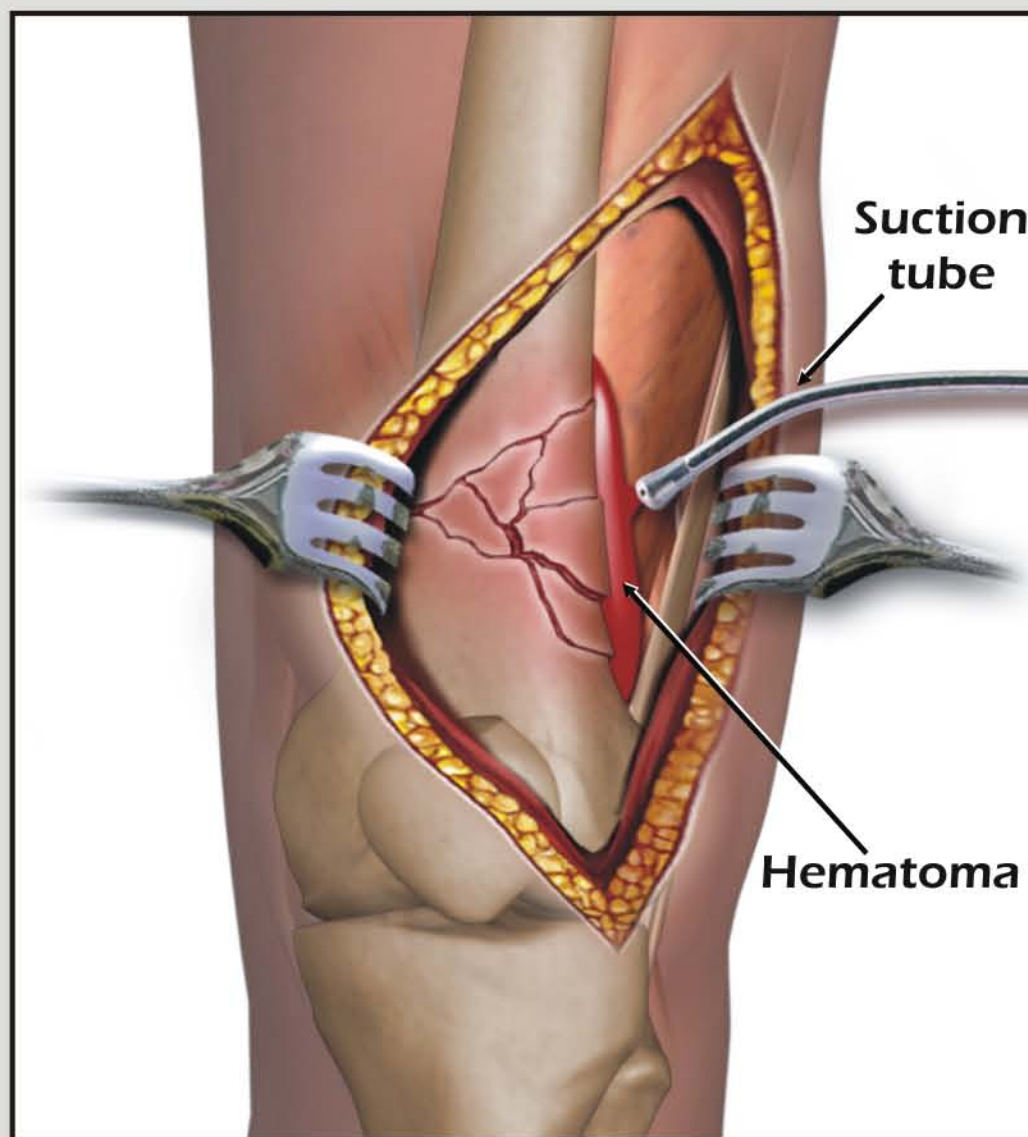


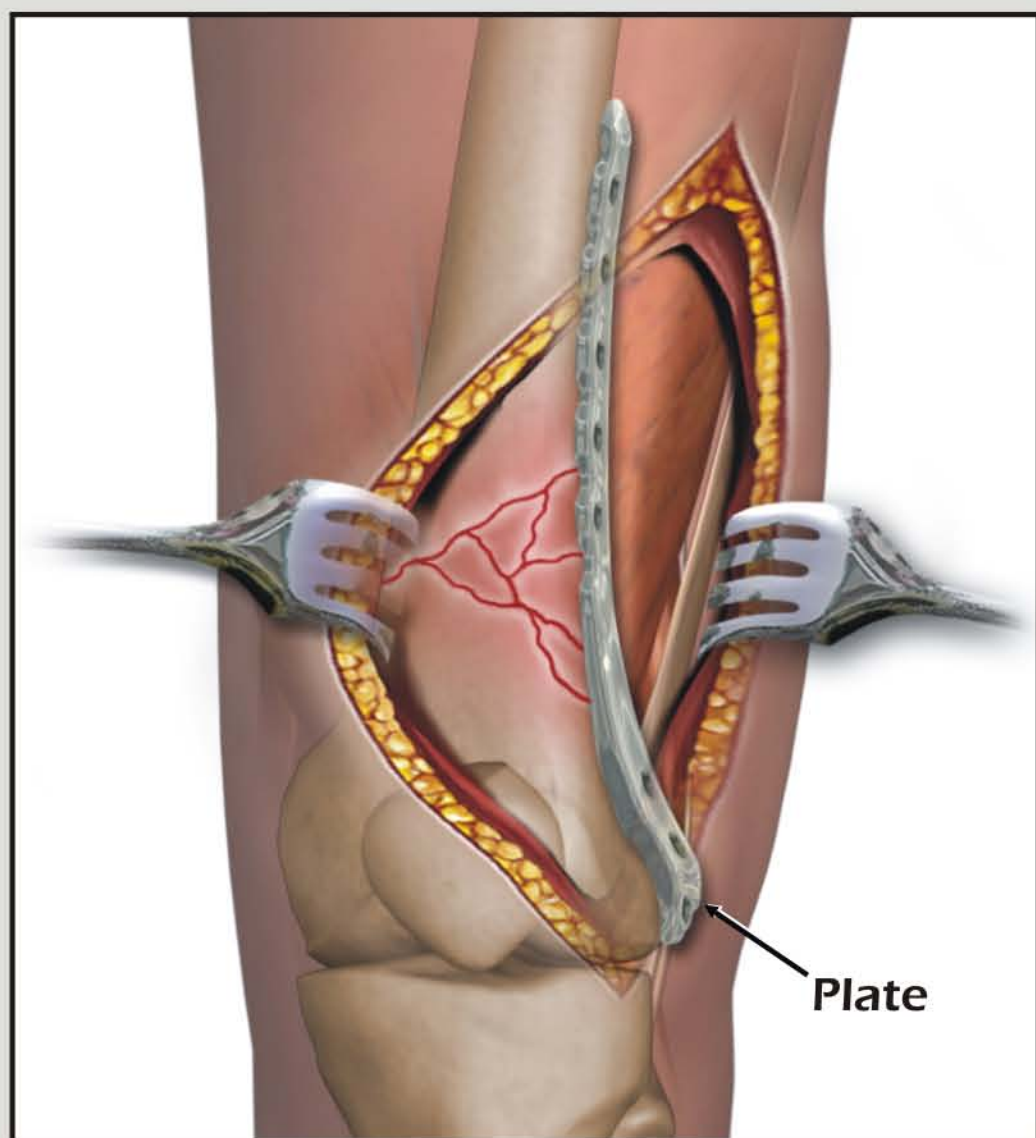
# OPEN REDUCTION & INTERNAL FIXATION of LEFT FEMUR FRACTURE



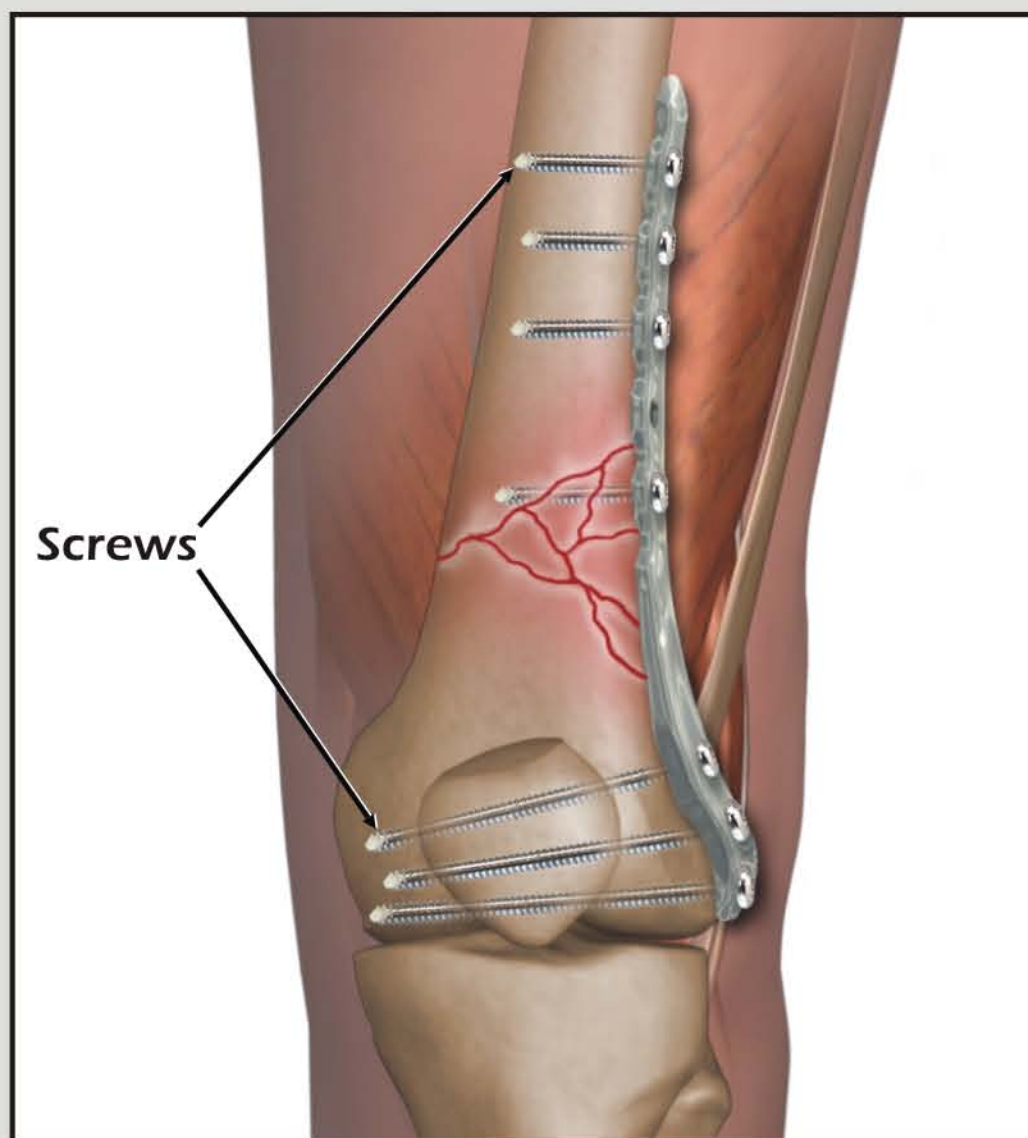
1. Incision and exposure of left comminuted femur fracture



2. Debridement and evacuation of hematoma



3. Reduction of fracture and placement of distal locking plate



4. Placement of locking screws