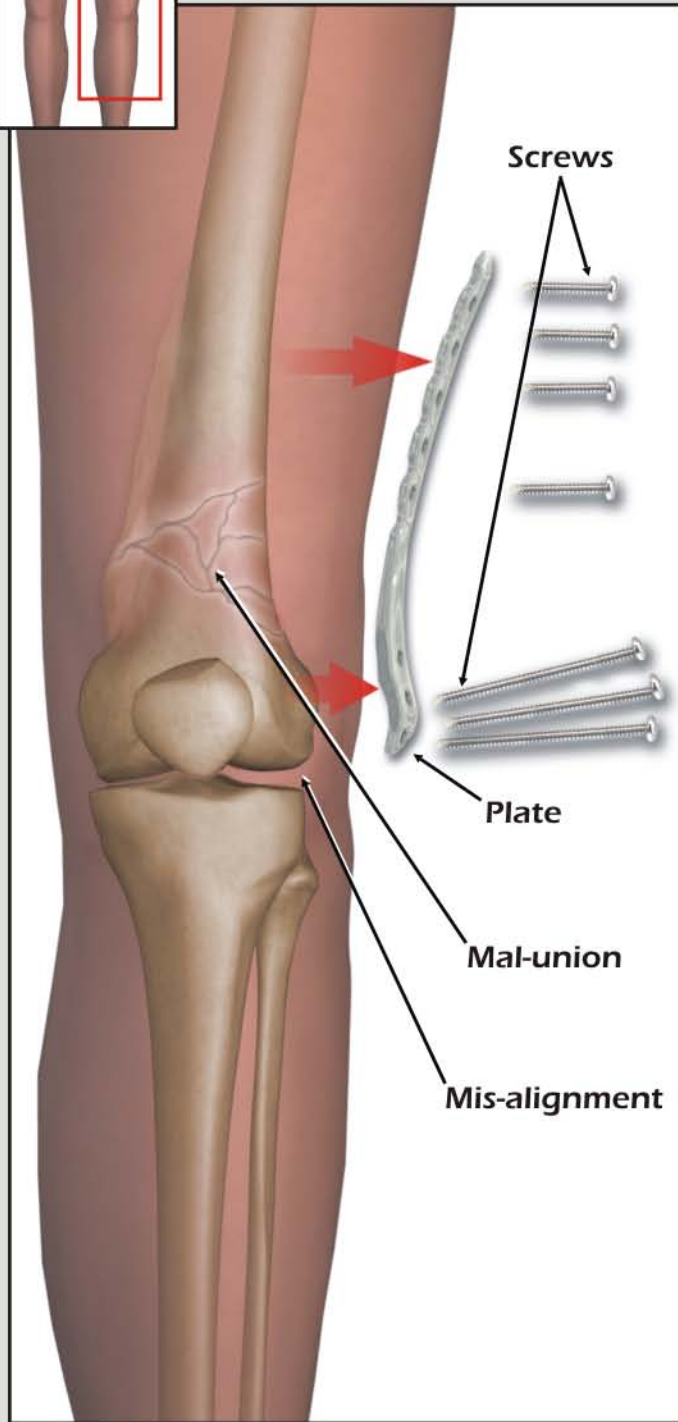
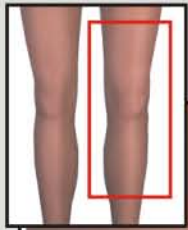
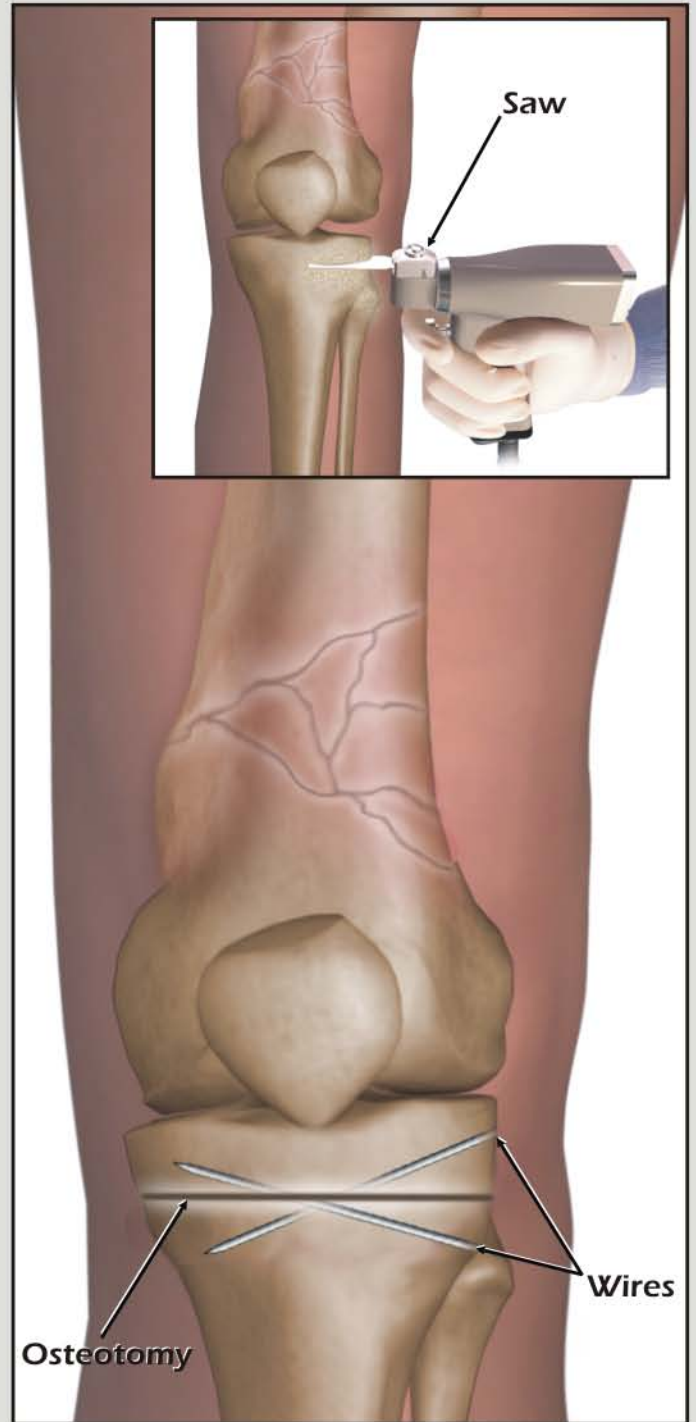


REMOVAL of HARDWARE with LEFT TIBIAL OSTEOTOMY



1. Removal of fixation hardware from mal-united femur



2. High tibial osteotomy with correction of alignment using guidewires