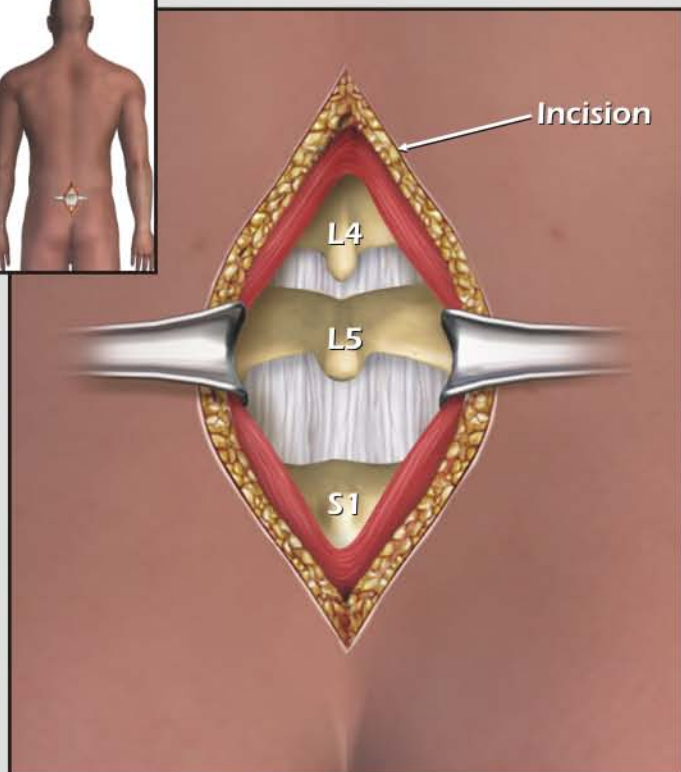
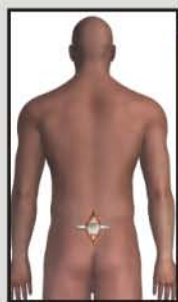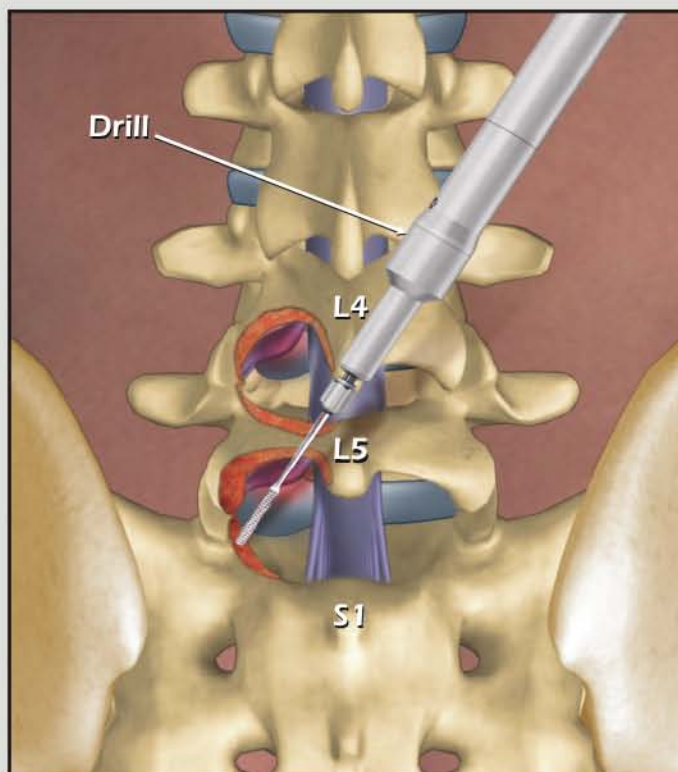


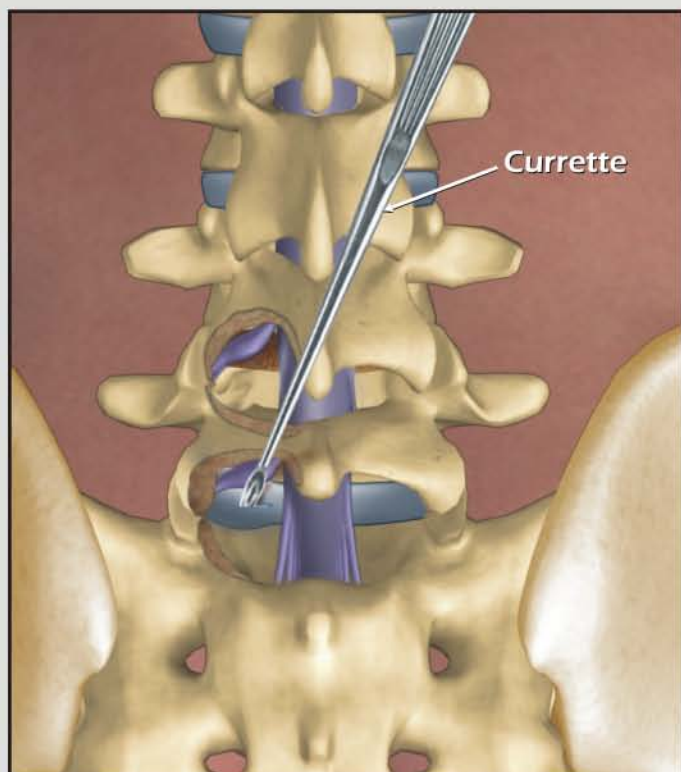
LEFT LUMBAR SPINE L4 to S1



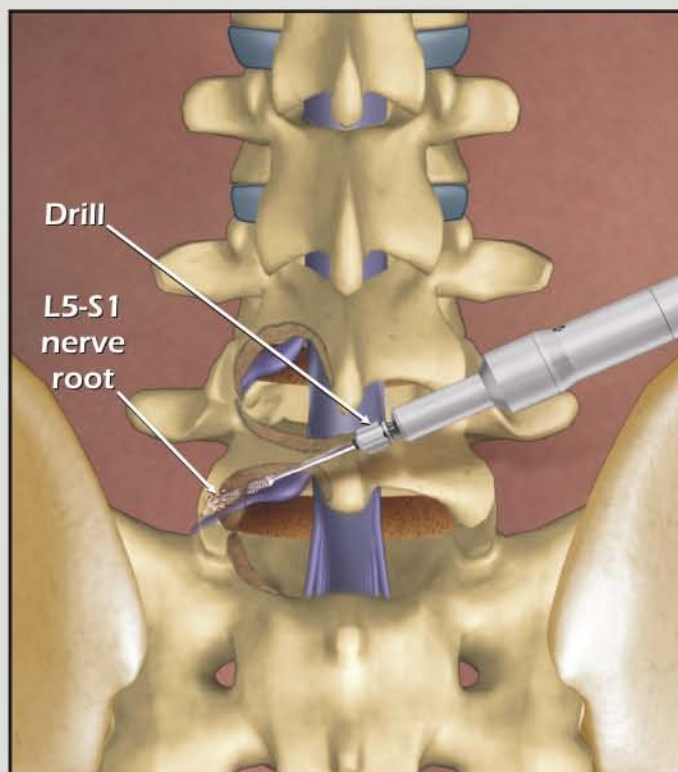
1. Incision and exposure of L4 to S1 spinous processes



2. Removal of left inferior 1/3 of the L4 & L5 lamina, superior 1/3 of the L5 & S1 lamina, and medial 1/3 of the L4-5 & L5-S1 facets



3. Removal of L4-5 and L5-S1 disc



4. Clearing of S1 nerve root canal