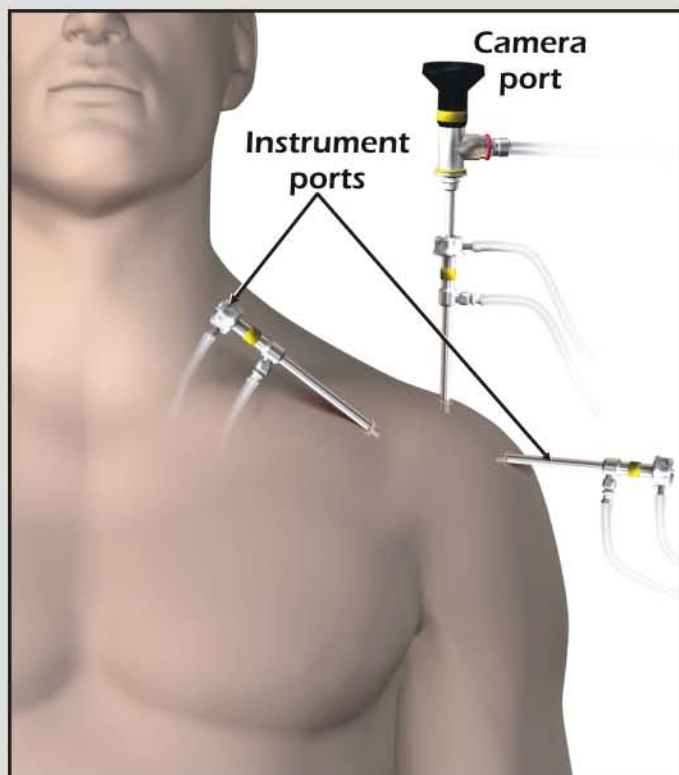
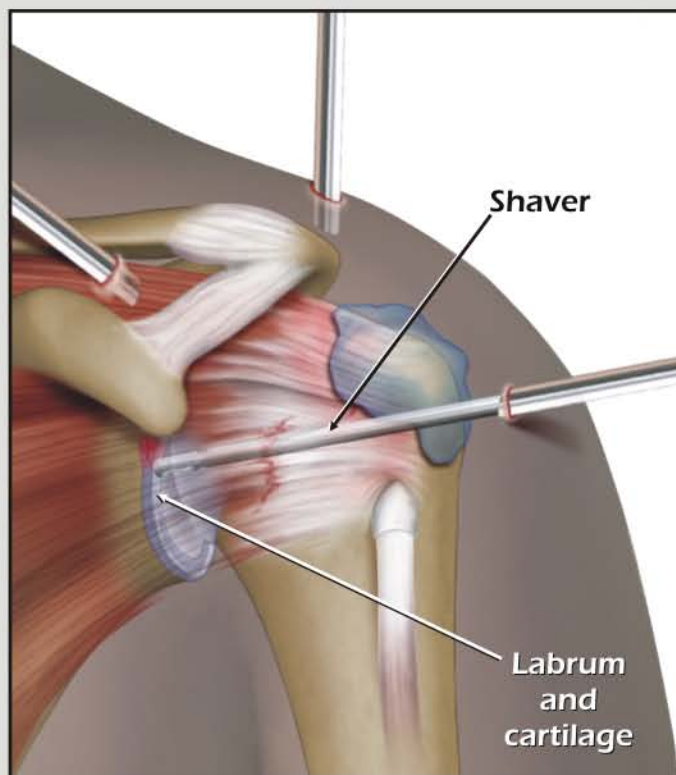


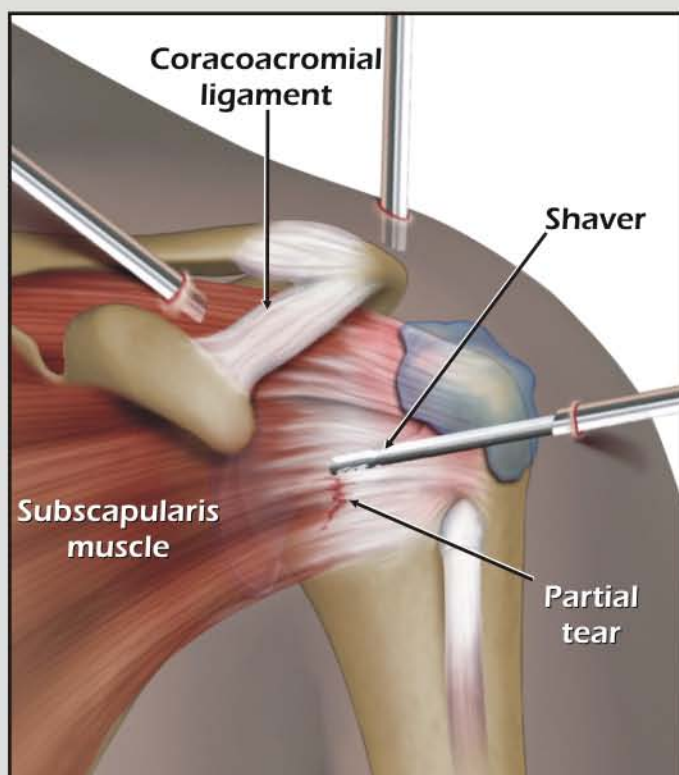
ARTHROSCOPIC REPAIR of LEFT SHOULDER



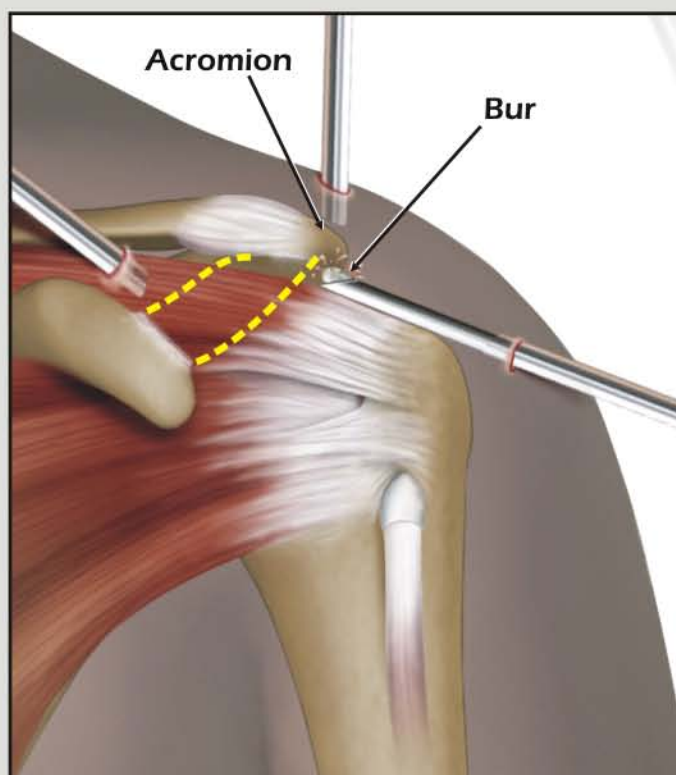
1. Insertion of arthroscopic instruments into the left shoulder



2. Debridement of unstable cartilage portions of the labrum



3. Debridement of subscapularis partial tear



4. Excision of hypertrophic coracoacromial ligament and acromioplasty