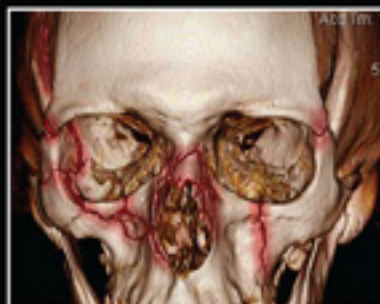

# INITIAL and RESIDUAL INJURIES

Right orbital extra-axial hematoma

Right lower eyelid ectropion defect

Right tear duct stent



Multiple facial fractures

Pulmonary embolus and insertion of Greenfield filter

Lumbosacral derangement with L4-5 disc protrusion and L5-S1 disc bulge

Left thigh swelling

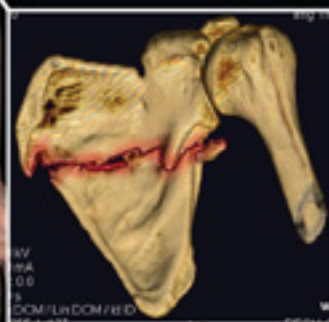
Left calf, ankle and foot tissue edema

Cerebral concussion, traumatic brain injury and neuropsychological impairment

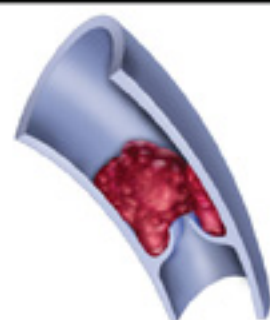
Loss of sense of smell

Left first rib fracture

Left shoulder adhesive capsulitis with pain and limited range of motion



Comminuted left scapula fracture



Post-traumatic iliofemoral deep vein thrombosis

