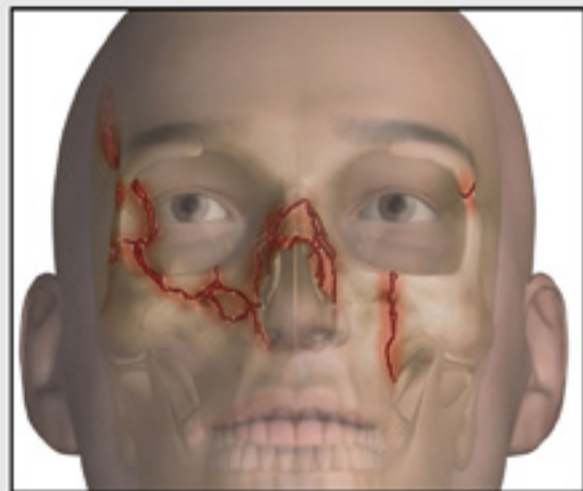
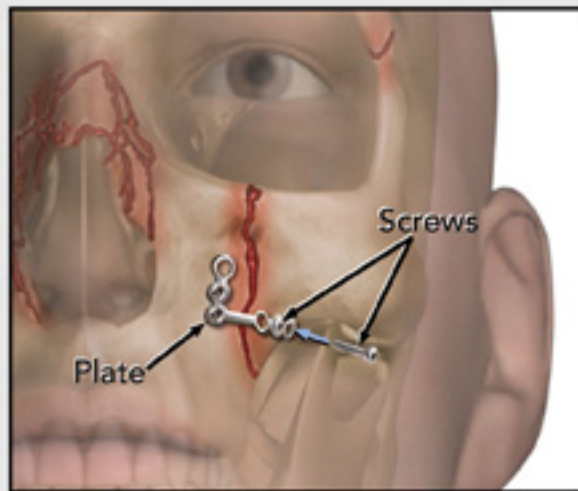


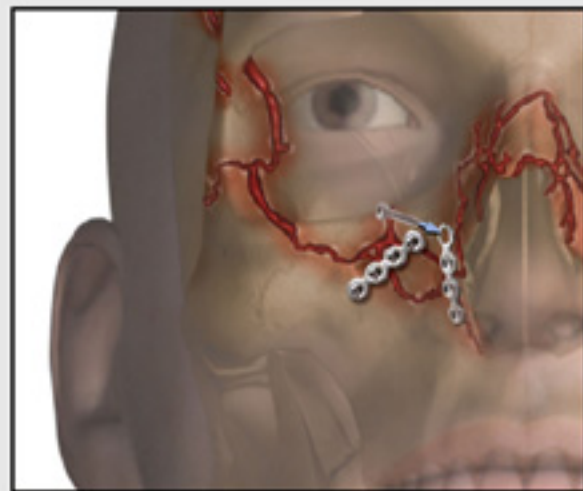SURGERY: 04/06/06 FIXATION of FACIAL FRACTURES



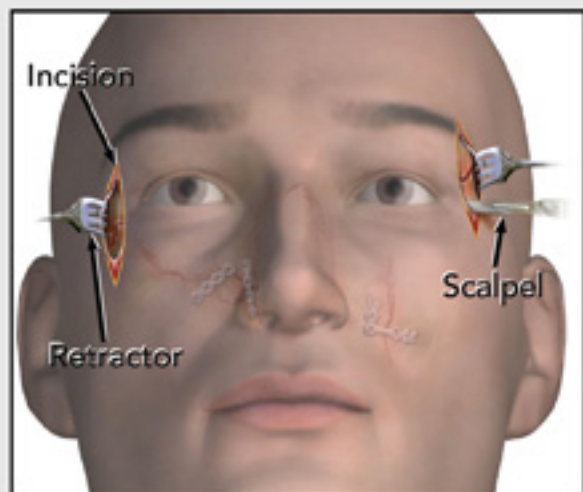
1. Multiple facial fractures.



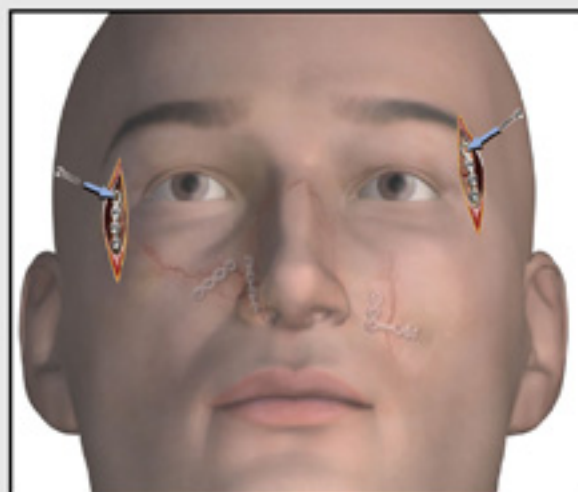
2. Stabilization of left malar fracture with plate and screws.



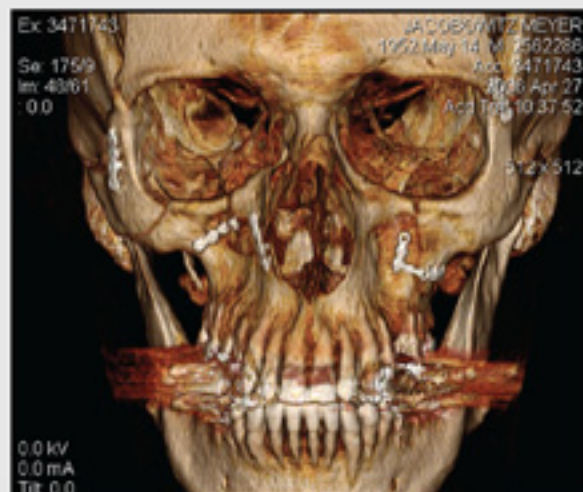3. Elevation and stabilization of right orbital rim fracture with plates and screws.



4. Incision and exposure of frontozygomatic buttresses.



5. Stabilization of bilateral buttresses with plates and screws.



6. CT-3D Reconstruction of post-op facial fractures with plates and screws 04/27/06.