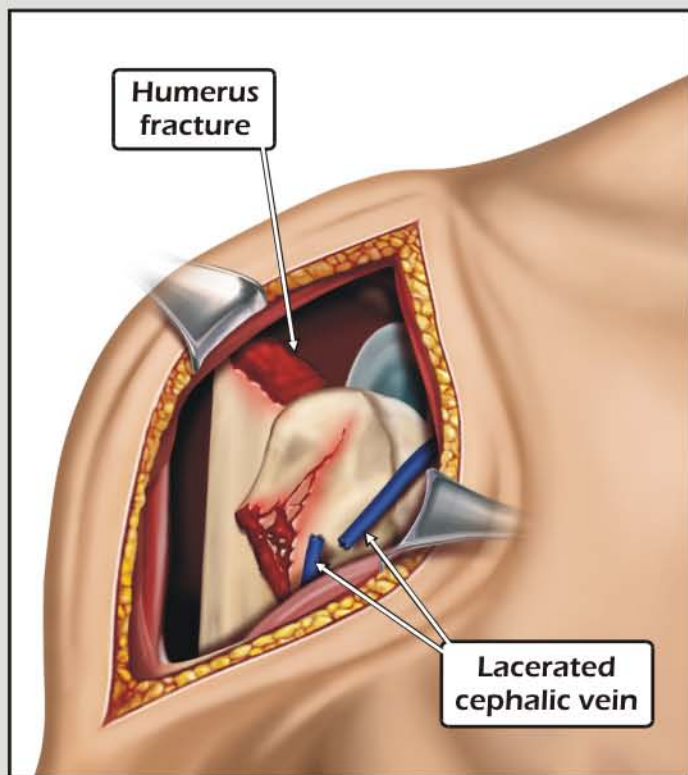
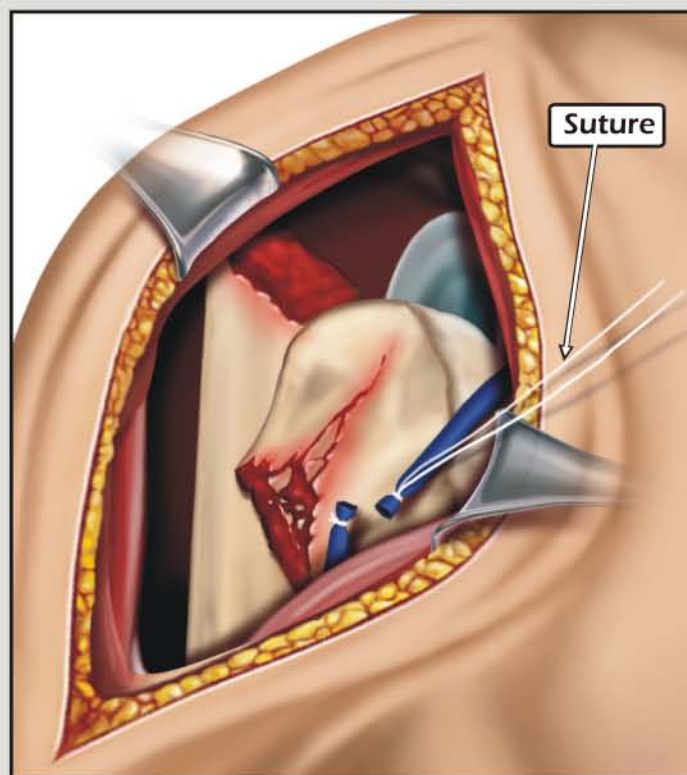


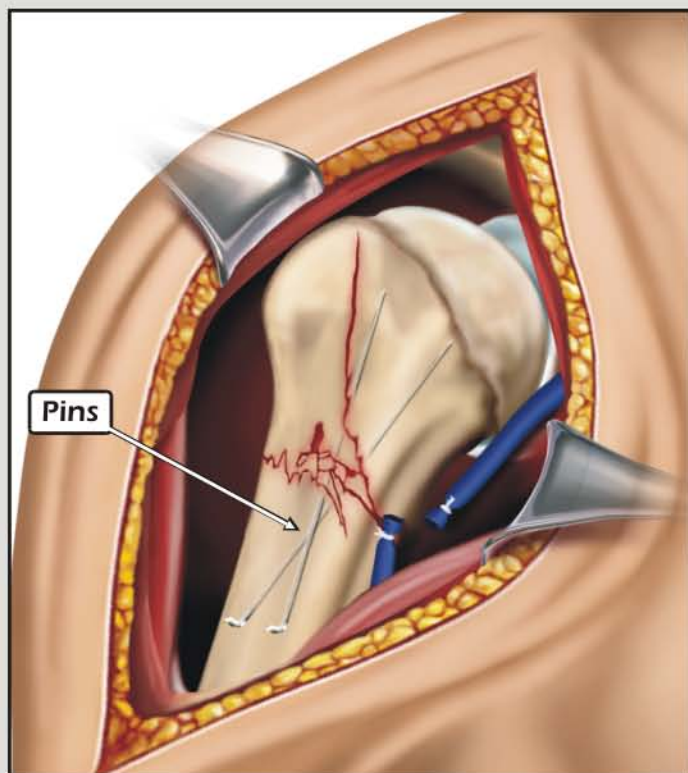
OPEN REDUCTION, INTERNAL FIXATION of the RIGHT HUMERUS



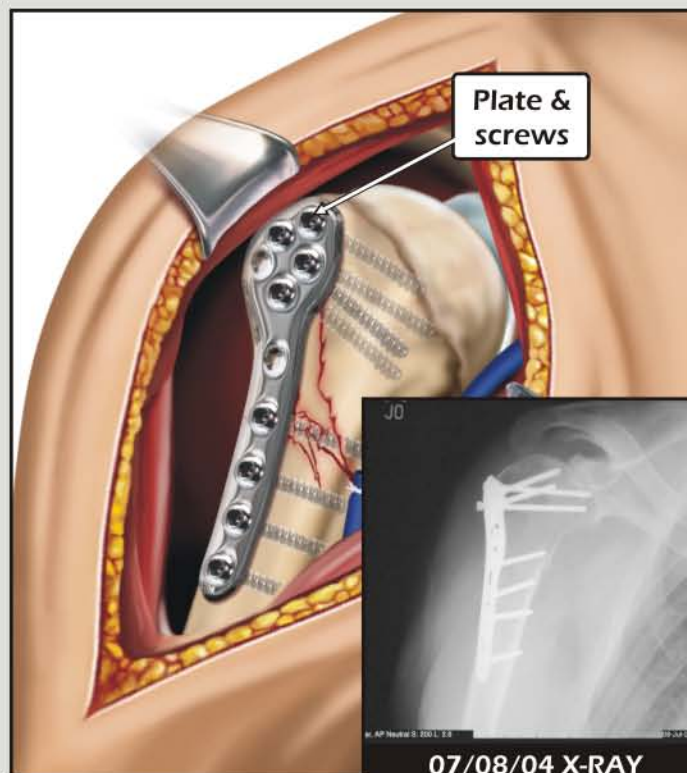
1. Incision and exposure



2. Ligation of cephalic vein



3. Reduction of fracture and placement of pins



4. Placement of plate and screws