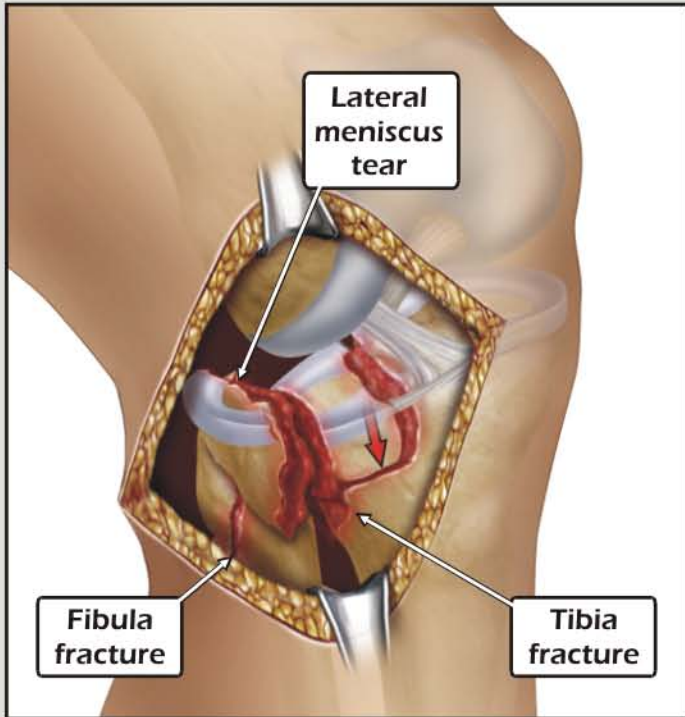
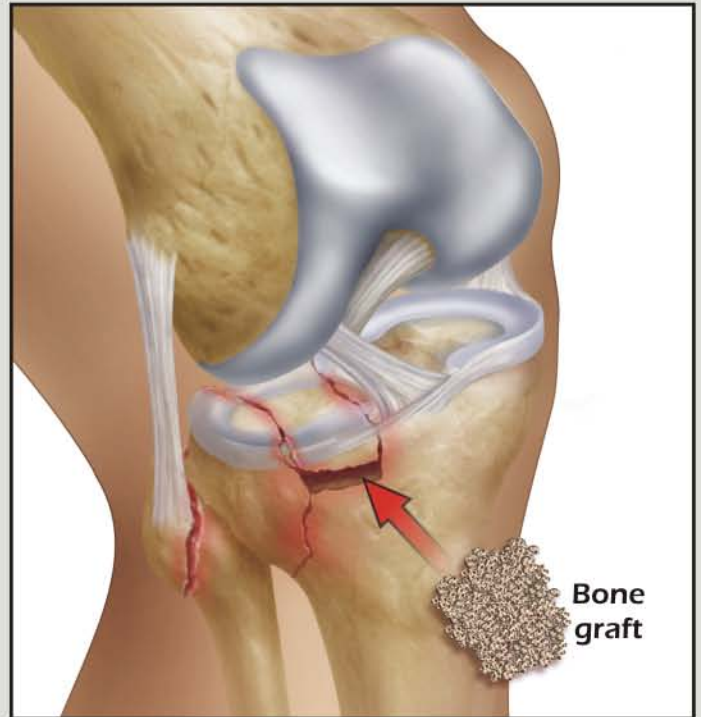


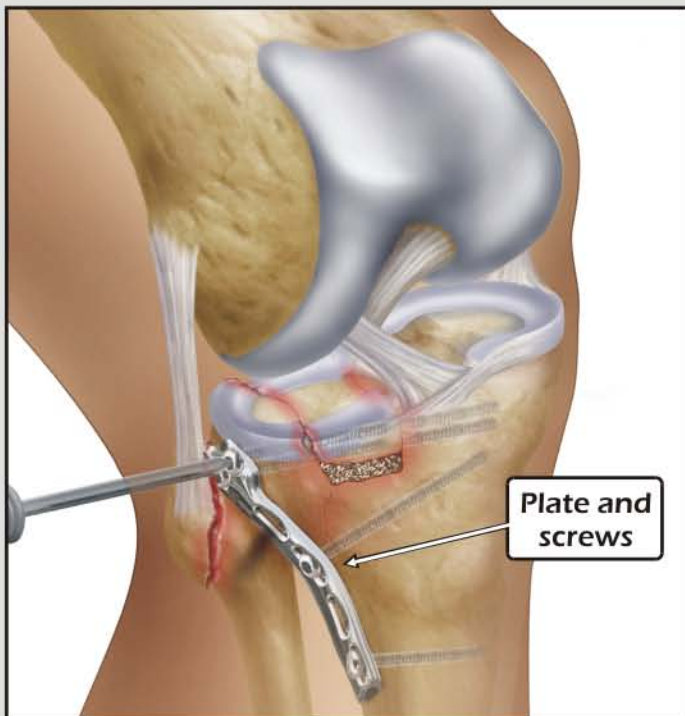
OPEN REDUCTION, INTERNAL FIXATION of the RIGHT TIBIAL PLATEAU with REPAIR of LATERAL MENISCUS



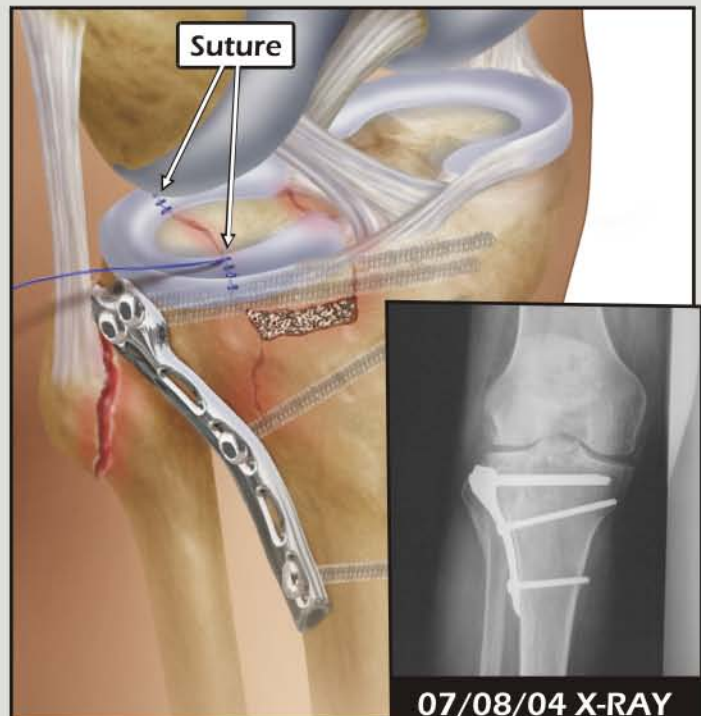
1. Transverse skin incision



2. Elevation of the fractured bone and placement of bone graft



3. Placement of locking plate and screws



4. Repair of the lateral meniscus