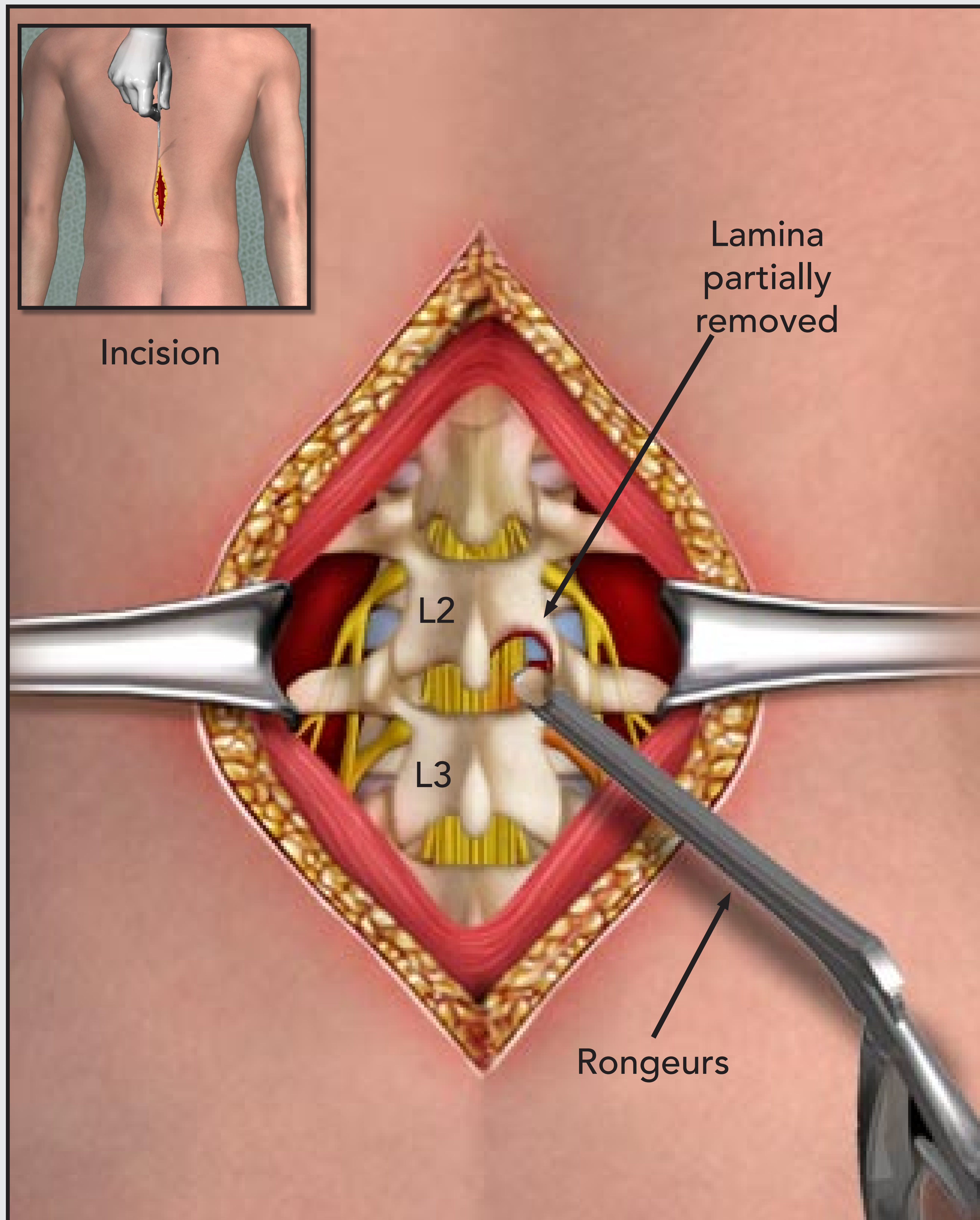
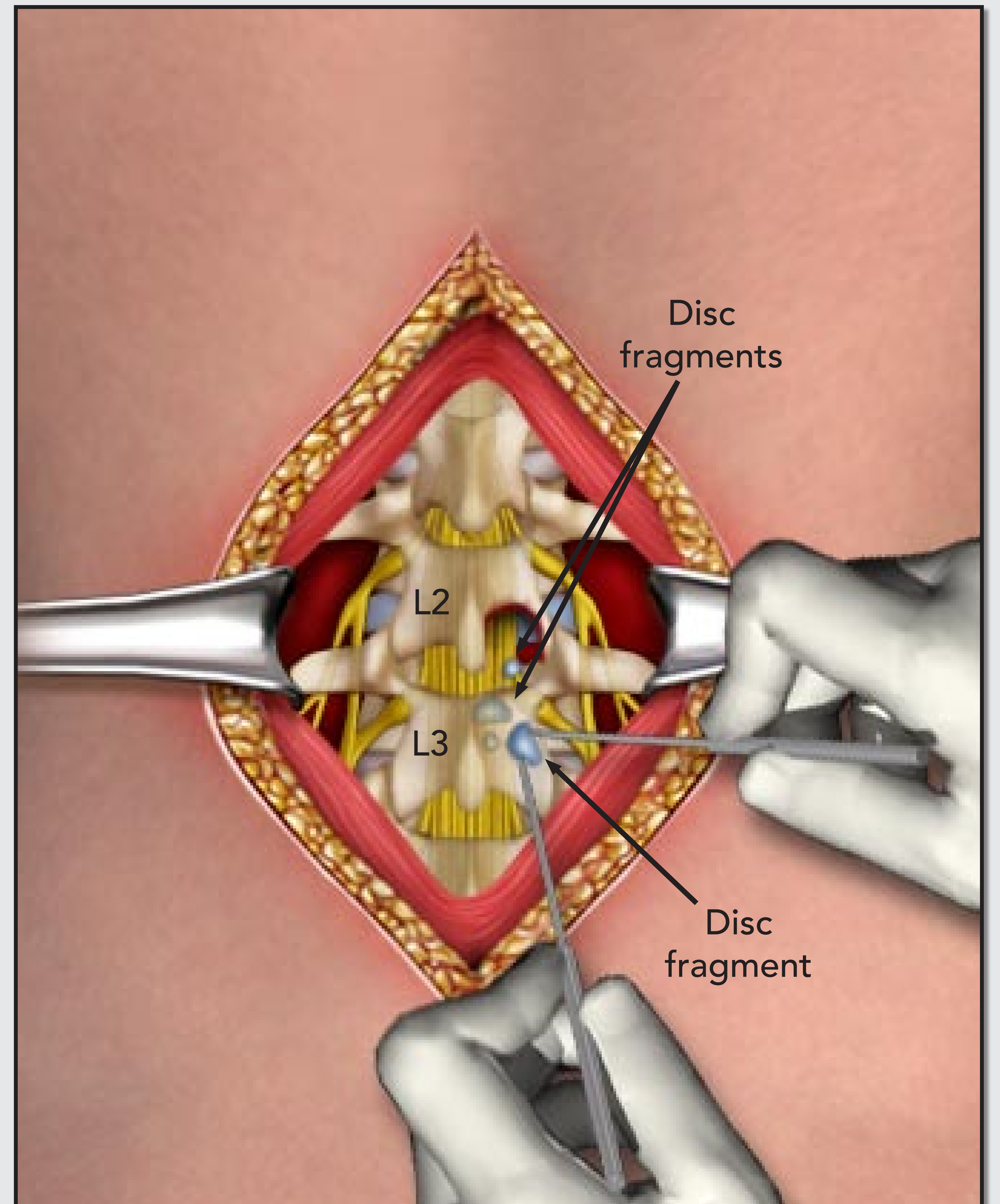


L2-3 LAMINOTOMY AND EXCISION OF EXTRUDED DISK FRAGMENTS



POSTERIOR VIEW

Right L2-3 laminotomy



POSTERIOR VIEW

Removal of disc fragments at the L3 level