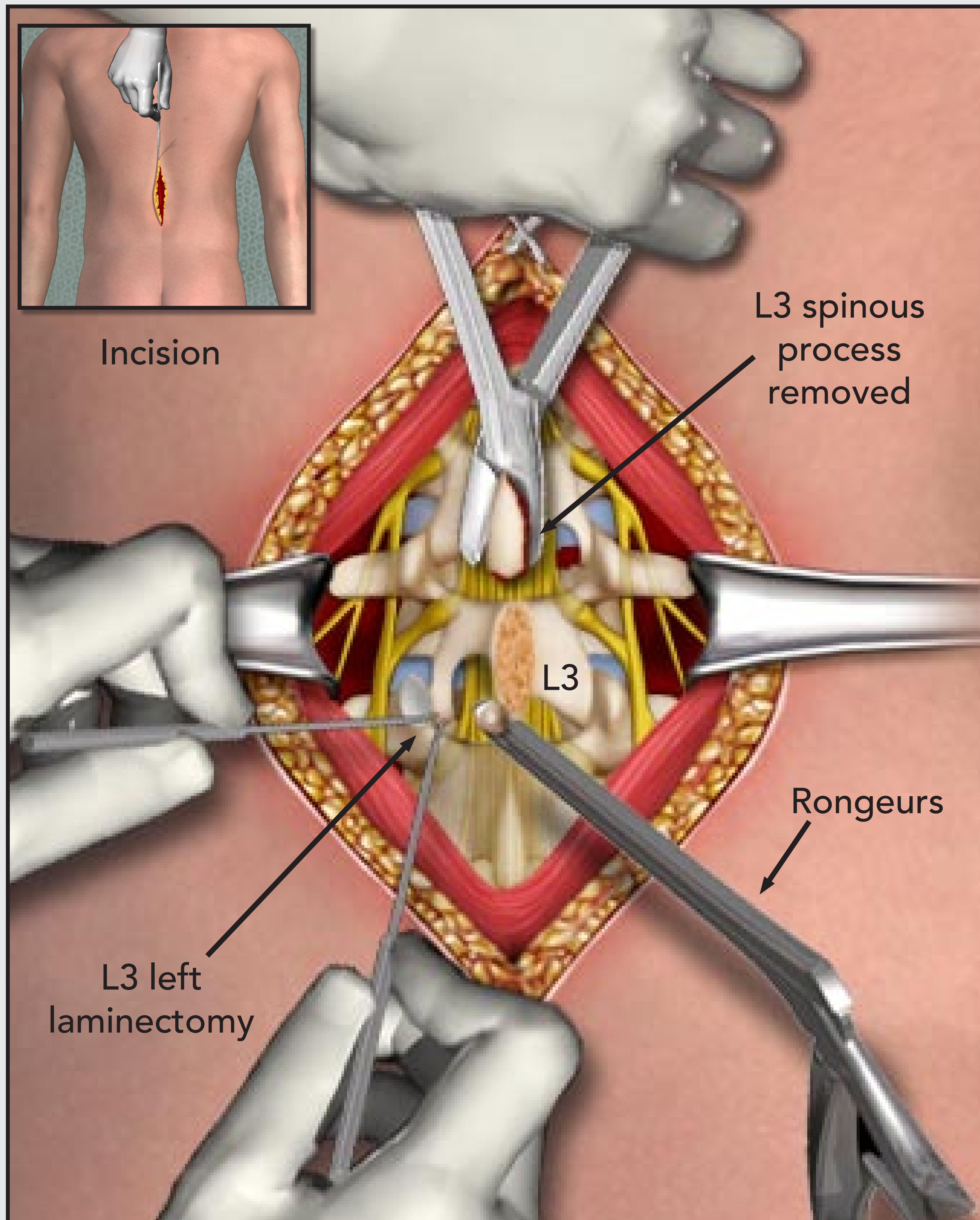
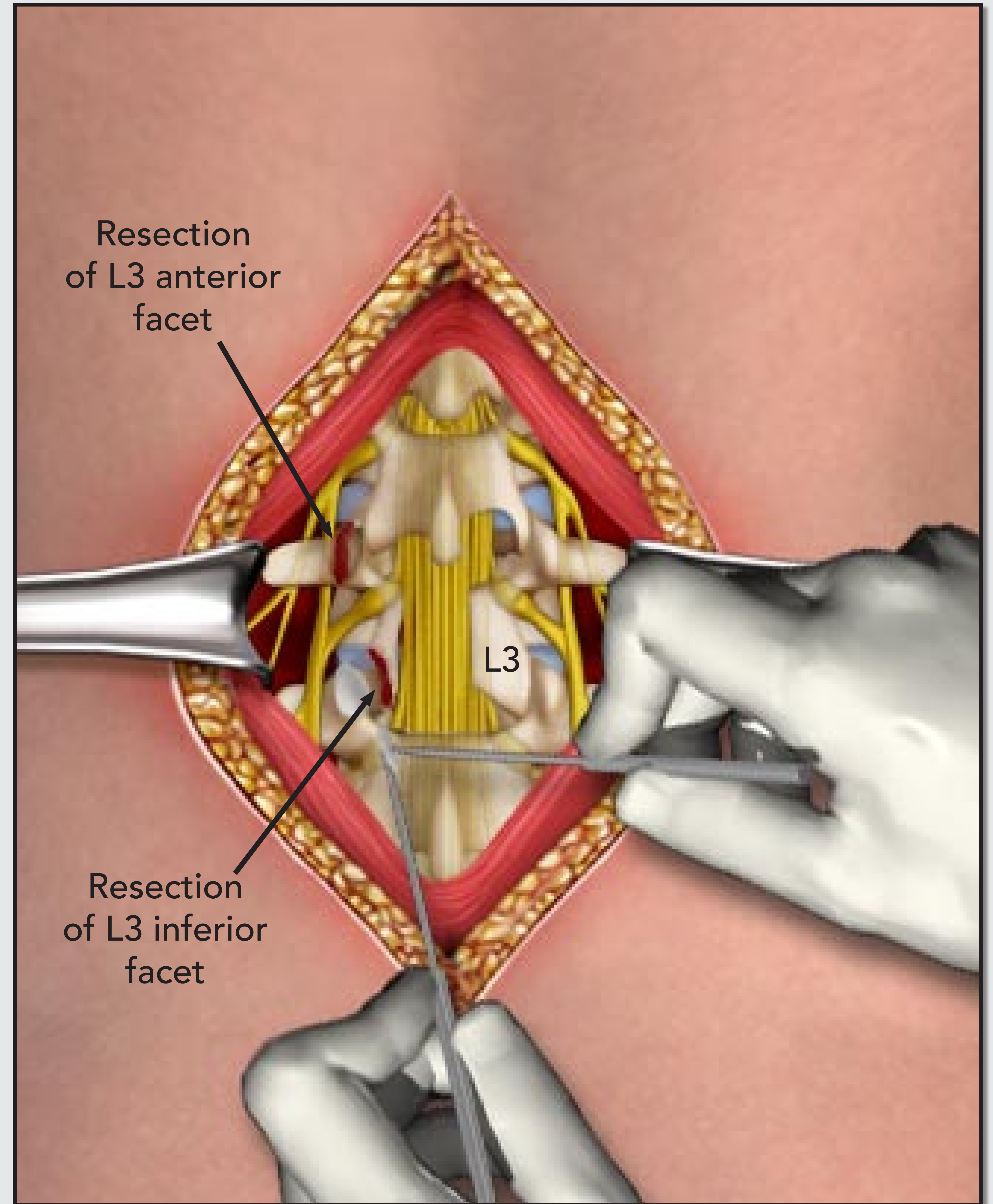


L3 LAMINECTOMY & PARTIAL RESECTION OF LEFT L3 FACET



POSTERIOR VIEW

Removal of L3 spinous process and left sided laminectomy



POSTERIOR VIEW

Partial resection of the left L3 anterior and inferior facet