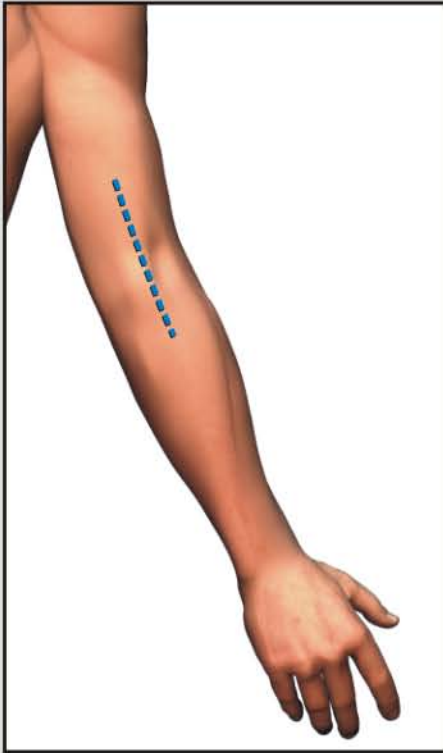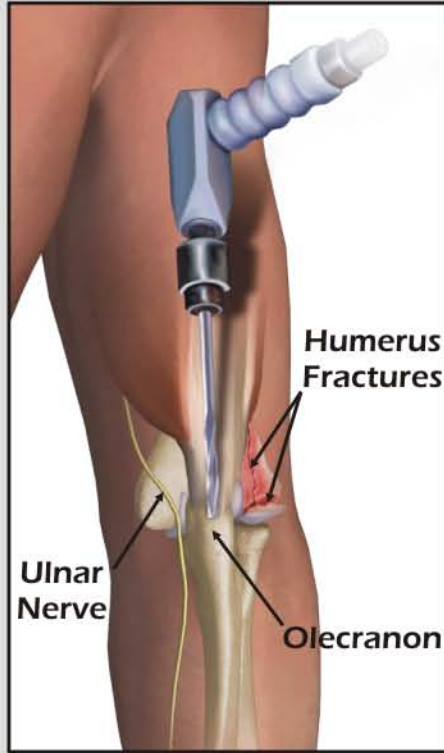


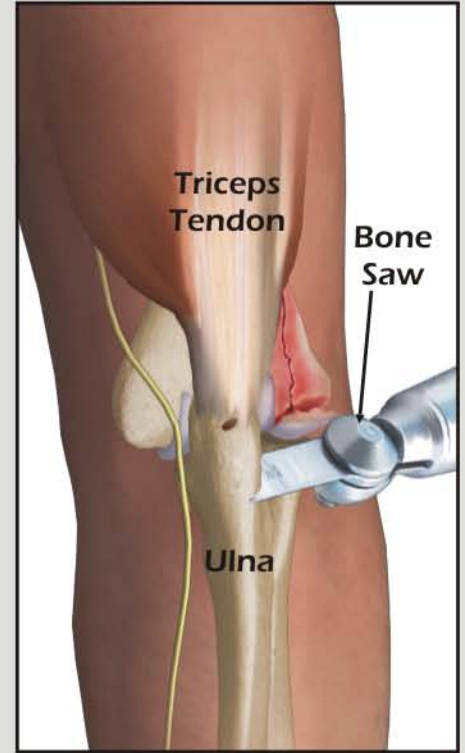
OPEN REDUCTION INTERNAL FIXATION OF HUMERUS FRACTURE AND ULNAR NERVE TRANSPOSITION



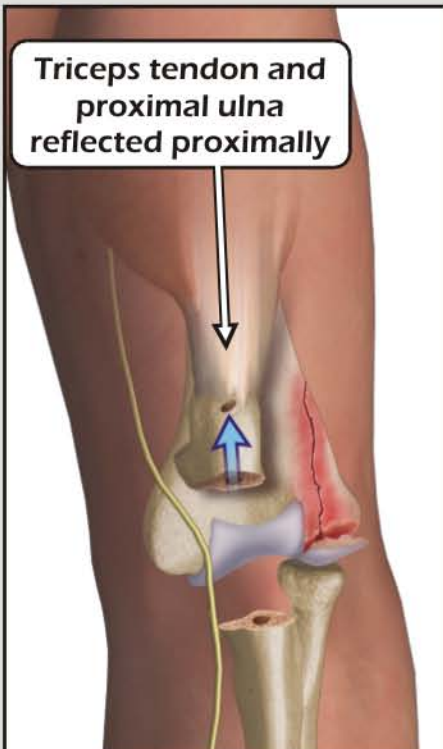
1. Site of Incision



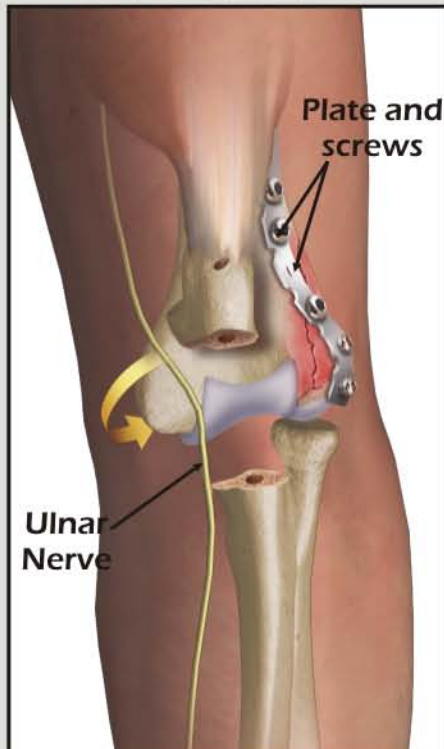
2. Drilling and tapping of olecranon



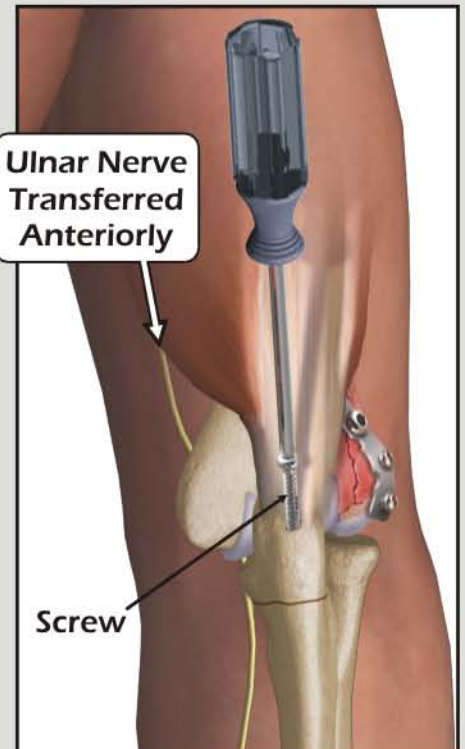
3. Osteotomy of ulna



4. Reflection of triceps and ulna for joint exposure



5. Fixation of plate and ulnar nerve transfer



6. Proximal ulna reattached with screw